

Dairy Cattle Hoof Health



January 2016

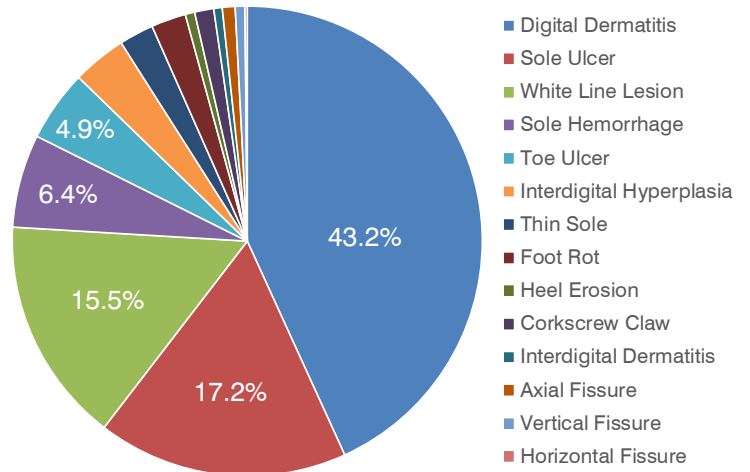
<http://dairyhoofhealth.info>

5 Lesions Account for 87% of Hoof Issues

Between October 2009 and November 2012, 7 Alberta hoof trimmers recorded hoof lesion occurrence during regular trimming visits using the Hoof Supervisor® computerized recording system. A total of 40,558 individual cows were examined in 158 herds across the province; 51% of these cows had one or more of the 14 claw lesions being recorded.

Digital Dermatitis (DD) was by far the most common lesion among the cows examined, accounting for 43.2% of all lesions recorded. DD, commonly called 'hairy heel warts', 'Mortellaro's disease' or 'strawberry foot rot' is a contagious infection caused by bacteria that thrive in moist, low-oxygen (anaerobic) environments such as manure and wet, contaminated bedding.

Next in order of prevalence were 4 lesions related to 'claw horn disruption' (CRD): sole ulcer, white line lesion, sole hemorrhage and toe ulcer. Together these four lesions accounted for 44.1% of all lesions recorded. Traditionally, these lesions were thought to result from feeding high-energy diets, leading to ruminal acidosis and laminitis—inflammation of the small blood vessels in the claw-forming tissue of the hoof.



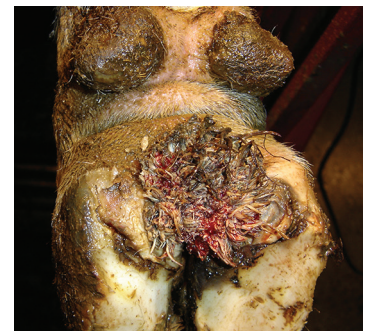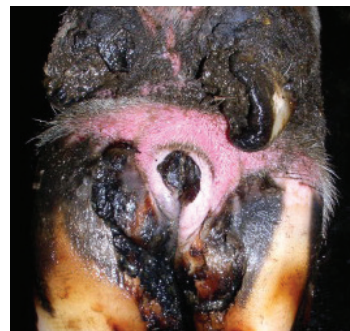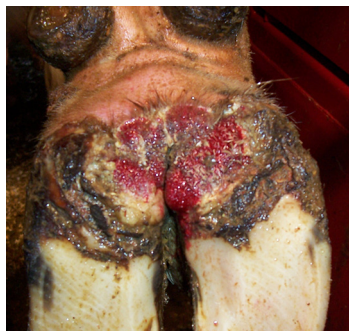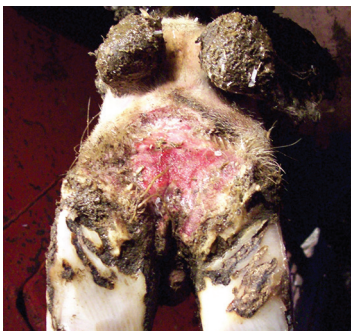More recent research evidence suggests that events around calving may cause structural changes in tissues that suspend the pedal bone inside the hoof. Another possibility is that low condition score (<2) at calving results in thinning of the digital fat pad than provides a cushion under the bone.

Digital Dermatitis: Hoof Health Issue #1

Digital dermatitis (DD) is an infectious lesion of the bovine hoof, usually found on the heel bulb around the end of the interdigital cleft. Rarely, DD may be found in the interdigital space, associated or not with interdigital hyperplasia and, less frequently, on the skin above the coronary band or close to the dewclaws. More than 90% of DD lesions are found on the rear hooves. Abraded skin constantly exposed to a wet, manure contaminated walking surface provides ideal conditions for infection. Typical DD lesions are illustrated below.

Spiral-shaped bacteria (spirochetes) of the *Treponeme* family are thought to be the primary pathogen in advanced stages of infection; other organisms may be involved in earlier stages. Whether or not DD and interdigital dermatitis are caused by the same organism(s) is controversial. There have also been several reports of DD-like infections in 'non-healing' cases of white line lesions and sole ulcers.

Much more information about the pathology, prevention, control and treatment of DD is available on the Dairy Cattle Hoof Health blog site: <http://dairyhoofhealth.info>.



Why Footbaths Fail

Foot bathing is the most important strategy for limiting the spread of digital dermatitis and other infectious hoof lesions. A study conducted on 18 Dutch dairy farms provided insight into how footbaths can go wrong. Footbaths failed to perform as expected because:

- ✓ The initial concentration of the preventive product was not adequate. The goal for these farms was to achieve a 4% concentration of formalin in footbaths prior to their use. Only 8 of 18 farms achieved this—initial formalin concentrations ranged from 0.9 to 9.6%. By the time of sampling after the second milking, only two herds had footbath formalin concentrations greater than 4%.
- ✓ Too many cow passages occurred. The concentration of formalin in the baths used by the study herds decreased by about 50% after 2.4 days, equivalent to about 300 cow passages. As a rule of thumb, this means that herds with 300 cows needed to change the bath after every milking, while herds with 50 cows should change it after six milkings, and so on.
- ✓ Footbaths were too small. A footbath should be 3 m long, 0.8 m wide and 0.15 m high. Shorter footbaths allow cows to step around or over the baths. Shallow footbaths hold too little solution to allow adequate contact of the chemical with the hoof. In the study herds, 50% of the baths were too small.
- ✓ Formalin concentration declined over time. A drop in bath volume due to evaporation or splashing, where baths are topped up by the addition of water, also decreases the concentration below the effective level. Topping up should have been done by adding more 4% formalin solution.
- ✓ Footbath solution is replaced by dirt and manure. Formalin concentration can decline although footbath volume may not change as spilled and splashed solution is replaced by urine, dirt and manure. Volume maintenance does not mean that formalin concentration has been maintained.



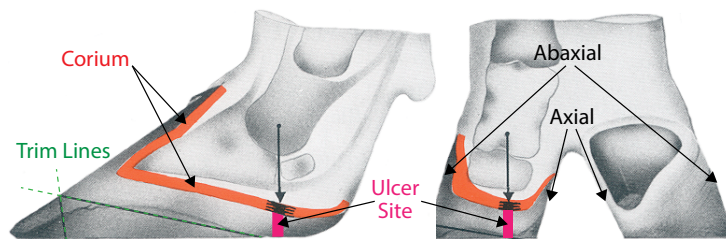
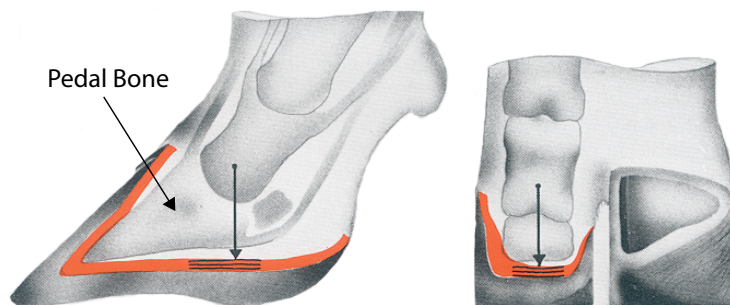
photo credit: Jamie Sullivan

What You Should Know About Sole Ulcers

Sole ulcers are among the most common causes of dairy cattle lameness. Why are they so common? In his classic book 'Cattle Footcare and Claw Trimming', Dr. Toussaint Raven explains:

The two diagrams below illustrate how the weight of the animal is transferred through the pedal bone onto the soles of each of the claws. When the claw is correctly placed on the walking surface (due to even wear or corrective trimming), weight is distributed over a relatively large area.

Under conditions of insufficient wear, a claw tends to become overgrown at the anterior (toe) end of the abaxial (outside) wall while the sole and heel bulb tend to crumble and wear off. A long wall, abaxially in the toe, plus a heel which is poorly developed on the axial side (inside) result in an unstable claw which tilts over axially and backwards, shifting weight backwards and to the axial side, as illustrated in the diagrams opposite.



The pedal bone will sag, putting extra pressure on a small area of the sole directly below the back end of the pedal bone, resulting in bruising or hemorrhage in the horn of the sole. Fluid and blood oozes from the corium, the source of new tissue, affecting new horn formation and staining the horn already formed. Locally, an irregular scar-like structure will appear in the horn—this is the typical sole ulcer seen in many, particularly older, cows (illustrated below).

